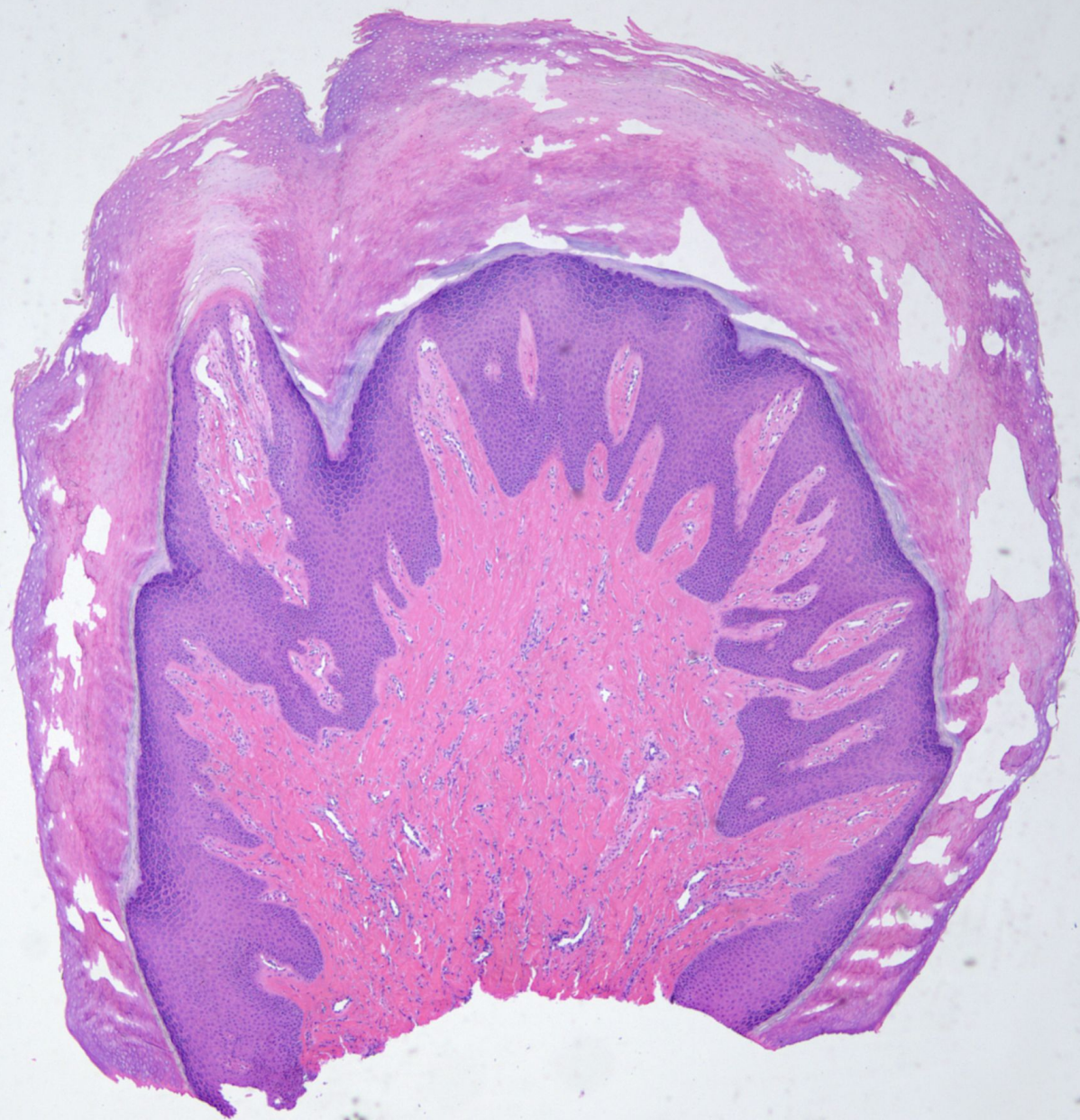
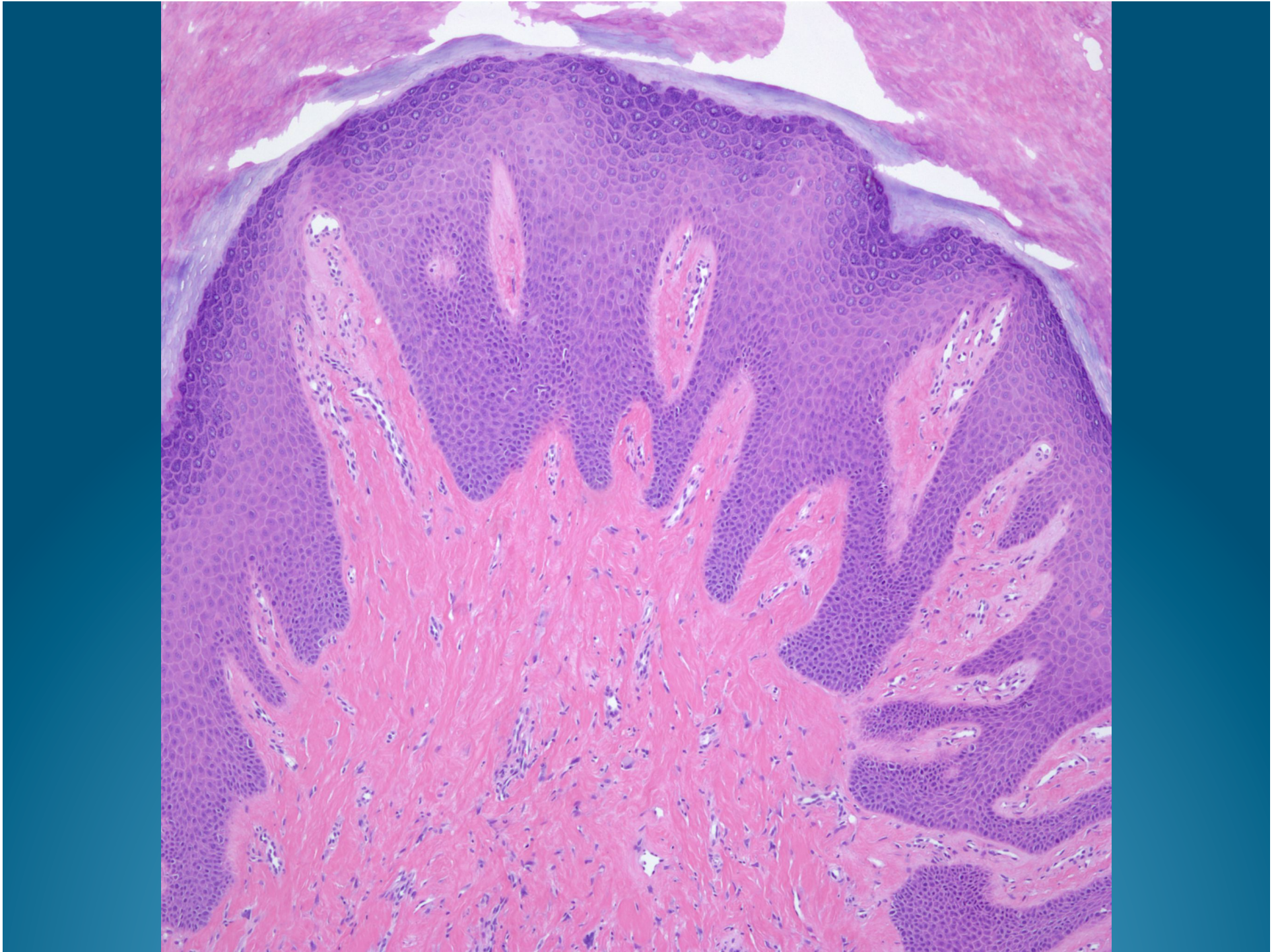
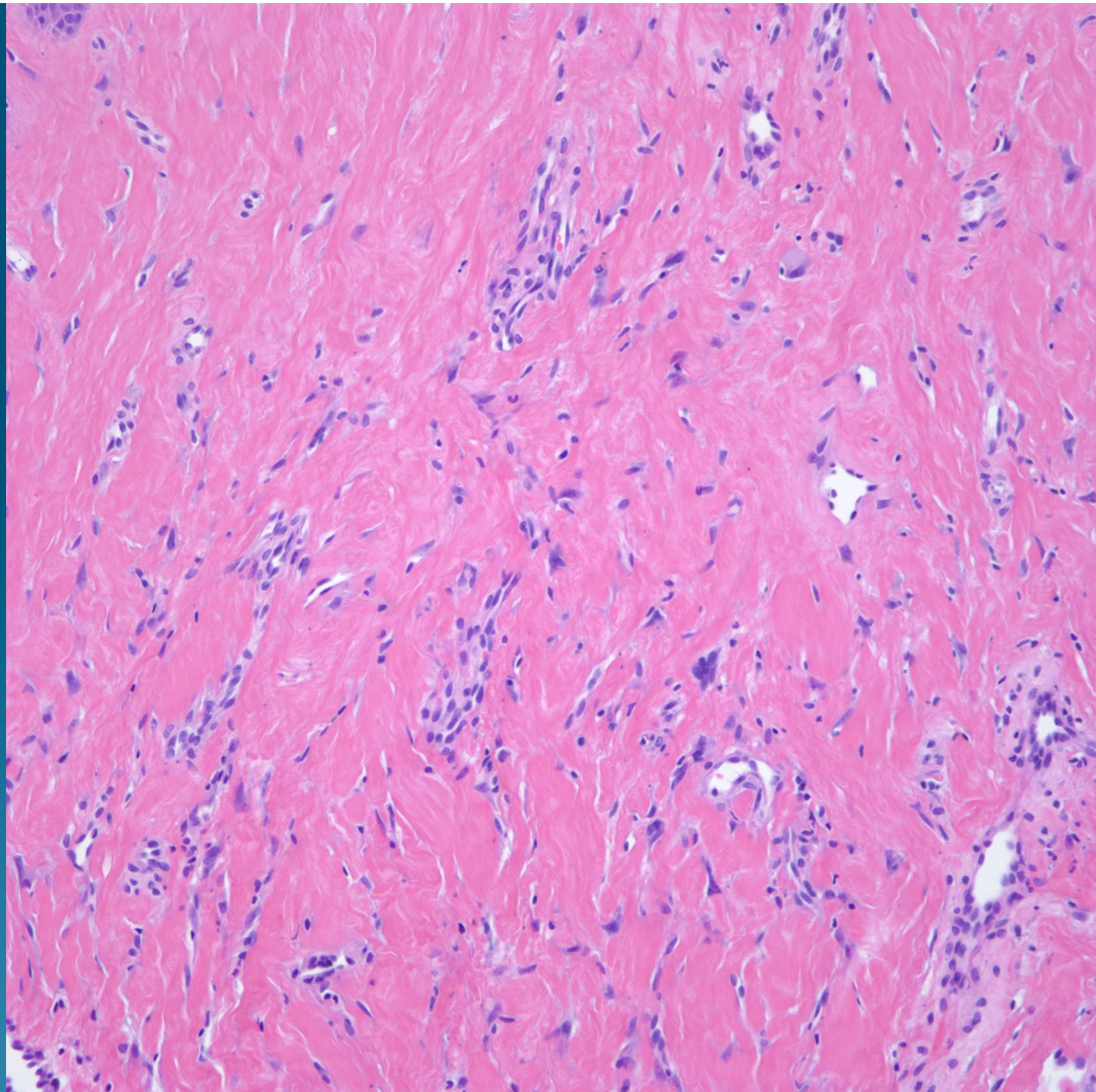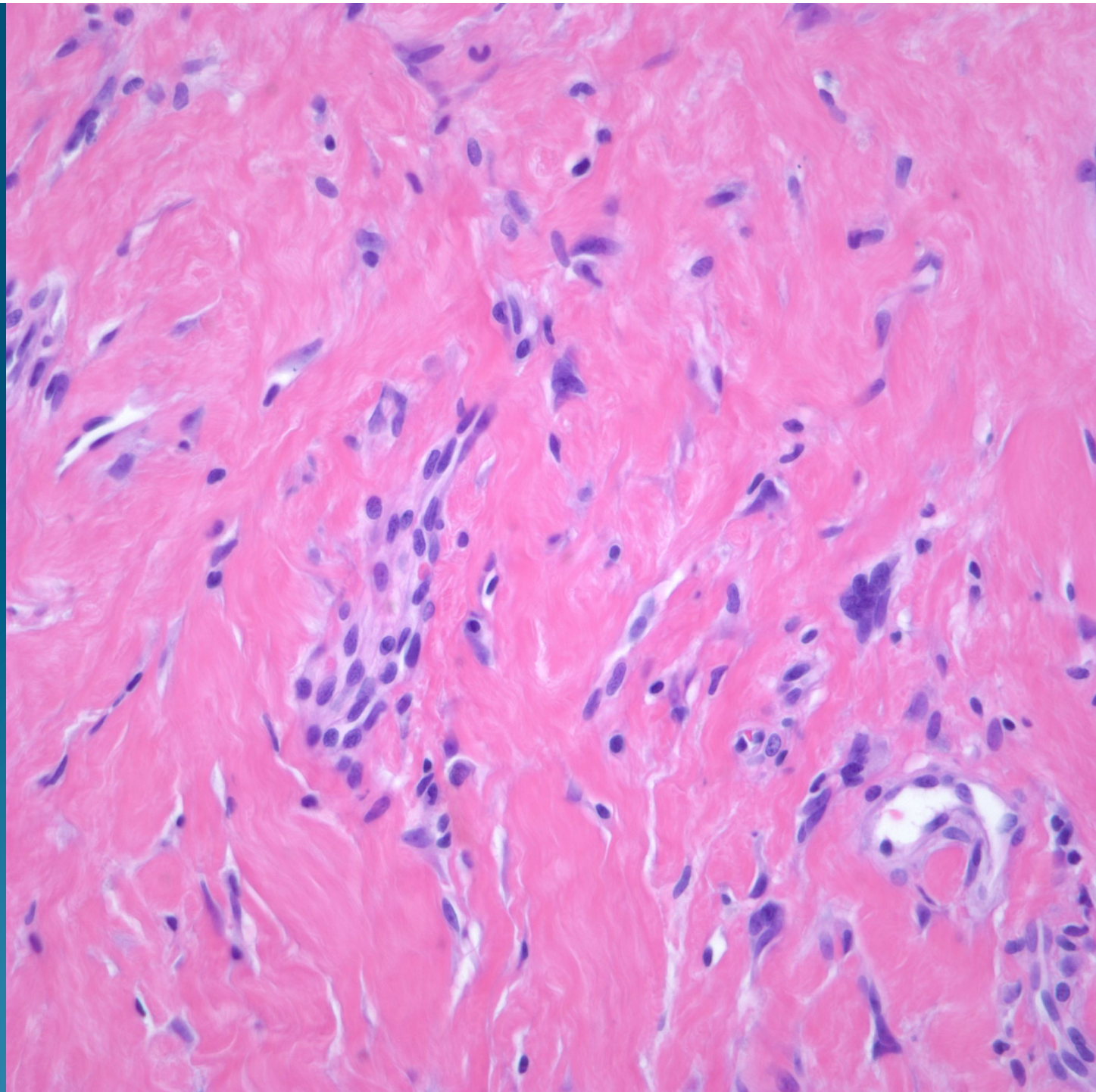What is the best diagnosis?

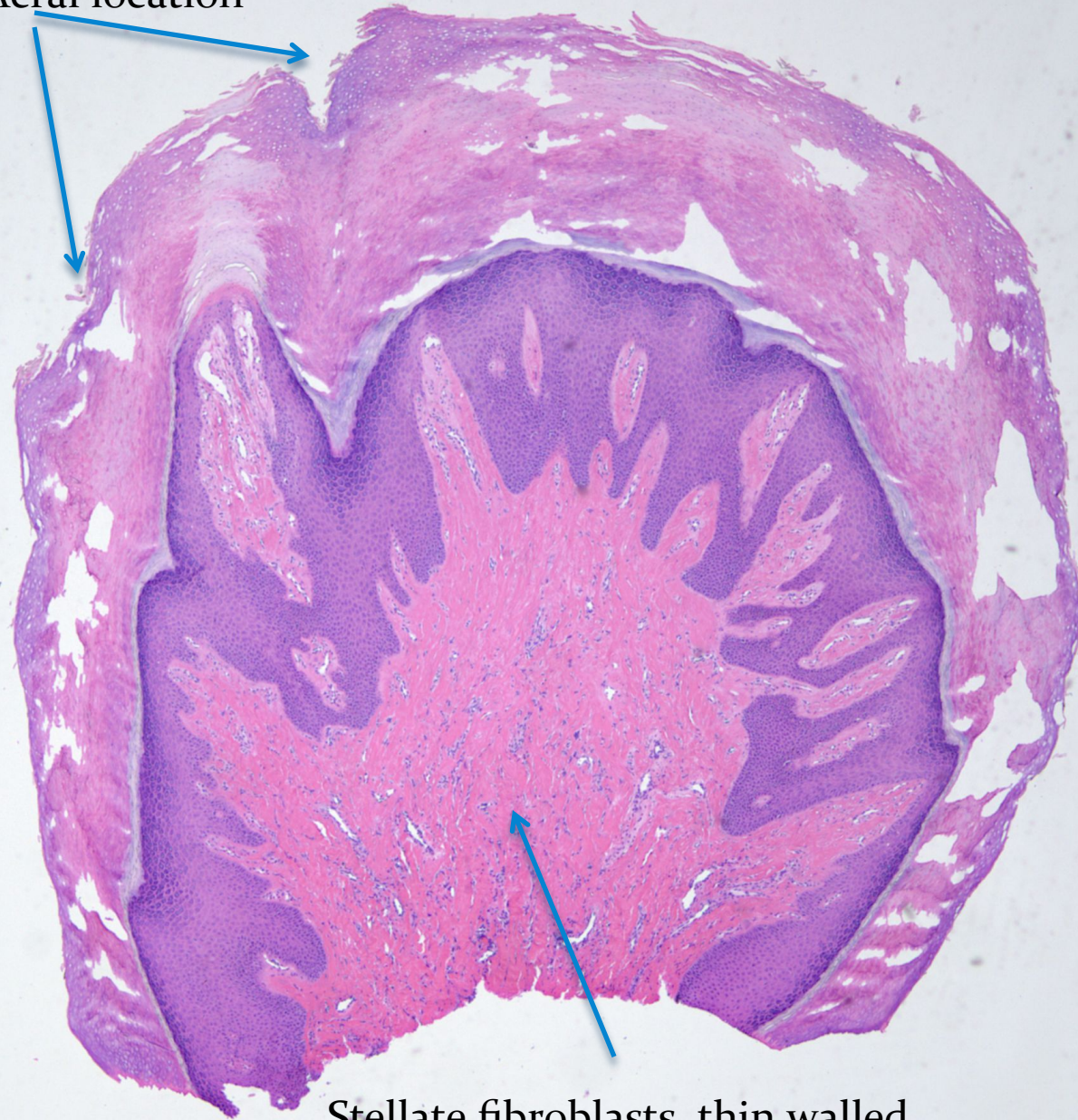
- A. Angiosarcoma
- B. Atypical Fibroxanthoma
- C. Xanthogranuloma
- D. Koenen's tumor
- E. Sclerotic Fibroma

Koenen's Tumor (Subungual Fibroma)

Notes

- This is an angiofibroma that occurs in the peri- or subungual location.
- Think fibrous papule arising on acral skin.
- There is a strong association with tuberous sclerosis.

Note Acral location



Stellate fibroblasts, thin walled
Capillary vessels, and fibroplasia